

PAPER NAME

WJCC-11-1992.pdf

AUTHOR

Nurussyariah Hammado

WORD COUNT

6731 Words

CHARACTER COUNT

38498 Characters

PAGE COUNT

16 Pages

FILE SIZE

5.0MB

SUBMISSION DATE

Apr 7, 2023 9:28 PM GMT+8

REPORT DATE

Apr 7, 2023 9:29 PM GMT+8

● 10% Overall Similarity

The combined total of all matches, including overlapping sources, for each database.

- 7% Internet database
- Crossref database
- Crossref Posted Content database

● Excluded from Similarity Report

- Publications database
- Submitted Works database
- Bibliographic material
- Quoted material
- Cited material
- Small Matches (Less than 10 words)
- Manually excluded sources

World Journal of *Clinical Cases*

World J Clin Cases 2023 March 26; 11(9): 1888-2122



REVIEW

- 1888 Endoscopic transluminal drainage and necrosectomy for infected necrotizing pancreatitis: Progress and challenges
Zeng Y, Yang J, Zhang JW

MINIREVIEWS

- 1903 Functional role of frontal electroencephalogram alpha asymmetry in the resting state in patients with depression: A review
Xie YH, Zhang YM, Fan FF, Song XY, Liu L
- 1918 COVID-19 related liver injuries in pregnancy
Sekulovski M, Bogdanova-Petrova S, Peshevska-Sekulovska M, Velikova T, Georgiev T
- 5 1930 Examined lymph node count for gastric cancer patients after curative surgery
Zeng Y, Chen LC, Ye ZS, Deng JY
- 9 1939 Laparoscopic common bile duct exploration to treat choledocholithiasis in situs inversus patients: A technical review
Chiu BY, Chuang SH, Chuang SC, Kuo KK
- 11 1951 Airway ultrasound for patients anticipated to have a difficult airway: Perspective for personalized medicine
Nakazawa H, Uzawa K, Tokumine J, Lefor AK, Motoyasu A, Yorozu T

ORIGINAL ARTICLE**Observational Study**

- 1963 Clinicopathological features and expression of regulatory mechanism of the Wnt signaling pathway in colorectal sessile serrated adenomas/polyps with different syndrome types
Qiao D, Liu XY, Zheng L, Zhang YL, Que RY, Ge BJ, Cao HY, Dai YC

Randomized Controlled Trial

- 1974 Effects of individual shock wave therapy *vs* celecoxib on hip pain caused by femoral head necrosis
Zhu JY, Yan J, Xiao J, Jia HG, Liang HJ, Xing GY

CASE REPORT

- 1985 Very low calorie ketogenic diet and common rheumatic disorders: A case report
Rondanelli M, Patelli Z, Gasparri C, Mansueto F, Ferraris C, Nichetti M, Alalwan TA, Sajoux I, Maugeri R, Perna S
- 1992 Delayed versus immediate intervention of ruptured brain arteriovenous malformations: A case report
Bintang AK, Bahar A, Akbar M, Soraya GV, Gunawan A, Hammado N, Rachman ME, Ulhaq ZS

- 2002** Children with infectious pneumonia caused by *Ralstonia insidiosa*: A case report
Lin SZ, Qian MJ, Wang YW, Chen QD, Wang WQ, Li JY, Yang RT, Wang XY, Mu CY, Jiang K
- 2009** Transient ischemic attack induced by pulmonary arteriovenous fistula in a child: A case report
Zheng J, Wu QY, Zeng X, Zhang DF
- 2015** Motor cortex transcranial magnetic stimulation to reduce intractable postherpetic neuralgia with poor response to other therapies: Report of two cases
Wang H, Hu YZ, Che XW, Yu L
- 2021** Small bowel adenocarcinoma in neoterminal ileum in setting of stricturing Crohn's disease: A case report and review of literature
Karthikeyan S, Shen J, Keyashian K, Gubatan J
- 2029** Novel combined endoscopic and laparoscopic surgery for advanced T2 gastric cancer: Two case reports
Dai JH, Qian F, Chen L, Xu SL, Feng XF, Wu HB, Chen Y, Peng ZH, Yu PW, Peng GY
- 2036** Acromicric dysplasia caused by a mutation of fibrillin 1 in a family: A case report
Shen R, Feng JH, Yang SP
- 2043** Ultrasound-guided intra-articular corticosteroid injection in a patient with manubriosternal joint involvement of ankylosing spondylitis: A case report
Choi MH, Yoon IY, Kim WJ
- 2051** Granulomatous prostatitis after bacille Calmette-Guérin instillation resembles prostate carcinoma: A case report and review of the literature
Yao Y, Ji JJ, Wang HY, Sun LJ, Zhang GM
- 2060** Unusual capitate fracture with dorsal shearing pattern and concomitant carpometacarpal dislocation with a 6-year follow-up: A case report
Lai CC, Fang HW, Chang CH, Pao JL, Chang CC, Chen YJ
- 2067** Live births from *in vitro* fertilization-embryo transfer following the administration of gonadotropin-releasing hormone agonist without gonadotropins: Two case reports
Li M, Su P, Zhou LM
- 2074** Spontaneous conus infarction with "snake-eye appearance" on magnetic resonance imaging: A case report and literature review
Zhang QY, Xu LY, Wang ML, Cao H, Ji XF
- 2084** Transseptal approach for catheter ablation of left-sided accessory pathways in children with Marfan syndrome: A case report
Dong ZY, Shao W, Yuan Y, Lin L, Yu X, Cui L, Zhen Z, Gao L
- 2091** Occipital artery bypass importance in unsuitable superficial temporal artery: Two case reports
Hong JH, Jung SC, Ryu HS, Kim TS, Joo SP

- 2098 Anesthetic management of a patient with preoperative R-on-T phenomenon undergoing laparoscopic-assisted sigmoid colon resection: A case report
Li XX, Yao YF, Tan HY
- 2104 Pembrolizumab combined with axitinib in the treatment of skin metastasis of renal clear cell carcinoma to nasal ala: A case report
Dong S, Xu YC, Zhang YC, Xia JX, Mou Y
- 2110 Successful treatment of a rare subcutaneous emphysema after a blow-out fracture surgery using needle aspiration: A case report
Nam HJ, Wee SY

LETTER TO THE EDITOR

- 2116 Are biopsies during endoscopic ultrasonography necessary for a suspected esophageal leiomyoma? Is laparoscopy always feasible?
Beji H, Chtourou MF, Zribi S, Kallel Y, Bouassida M, Touinsi H
- 12
2119 Vaginal microbes confounders and implications on women's health
Nori W, H-Hameed B

ABOUT COVER

14 Editorial Board Member of *World Journal of Clinical Cases*, Marilia Carabotti, MD, PhD, Academic Research, Medical-Surgical Department of Clinical Sciences and Translational Medicine, University Sapienza Rome, Rome 00189, Italy. mariliacarabotti@gmail.com

AIMS AND SCOPE

The primary aim of *World Journal of Clinical Cases (WJCC, World J Clin Cases)* is to provide scholars and readers from various fields of clinical medicine with a platform to publish high-quality clinical research articles and communicate their research findings online.

WJCC mainly publishes articles reporting research results and findings obtained in the field of clinical medicine and covering a wide range of topics, including case control studies, retrospective cohort studies, retrospective studies, clinical trials studies, observational studies, prospective studies, randomized controlled trials, randomized clinical trials, systematic reviews, meta-analysis, and case reports.

INDEXING/ABSTRACTING

The *WJCC* is now abstracted and indexed in Science Citation Index Expanded (SCIE, also known as SciSearch®), Journal Citation Reports/Science Edition, Current Contents®/Clinical Medicine, PubMed, PubMed Central, Scopus, Reference Citation Analysis, China National Knowledge Infrastructure, China Science and Technology Journal Database, and Superstar Journals Database. The 2022 Edition of Journal Citation Reports® cites the 2021 impact factor (IF) for *WJCC* as 1.534; IF without journal self cites: 1.491; 5-year IF: 1.599; Journal Citation Indicator: 0.28; Ranking: 135 among 172 journals in medicine, general and internal; and Quartile category: Q4. The *WJCC*'s CiteScore for 2021 is 1.2 and Scopus CiteScore rank 2021: General Medicine is 443/826.

RESPONSIBLE EDITORS FOR THIS ISSUE

Production Editor: *Ying-Yi Yuan*; Production Department Director: *Xiang Li*; Editorial Office Director: *Jin-Lei Wang*.

3 NAME OF JOURNAL

World Journal of Clinical Cases

ISSN

ISSN 2307-8960 (online)

LAUNCH DATE

April 16, 2013

FREQUENCY

Thrice Monthly

EDITORS-IN-CHIEF

Bao-Gan Peng, Jerzy Tadeusz Chudek, George Kontogeorgos, Maurizio Serati, Ja Hyeon Ku

EDITORIAL BOARD MEMBERS

<https://www.wjgnet.com/2307-8960/editorialboard.htm>

PUBLICATION DATE

March 26, 2023

COPYRIGHT

© 2023 Baishideng Publishing Group Inc

INSTRUCTIONS TO AUTHORS

<https://www.wjgnet.com/bpg/gerinfo/204>

GUIDELINES FOR ETHICS DOCUMENTS

<https://www.wjgnet.com/bpg/GerInfo/287>

GUIDELINES FOR NON-NATIVE SPEAKERS OF ENGLISH

<https://www.wjgnet.com/bpg/gerinfo/240>

1 PUBLICATION ETHICS

<https://www.wjgnet.com/bpg/GerInfo/288>

PUBLICATION MISCONDUCT

<https://www.wjgnet.com/bpg/gerinfo/208>

ARTICLE PROCESSING CHARGE

<https://www.wjgnet.com/bpg/gerinfo/242>

STEPS FOR SUBMITTING MANUSCRIPTS

<https://www.wjgnet.com/bpg/GerInfo/239>

ONLINE SUBMISSION

<https://www.f6publishing.com>



Delayed versus immediate intervention of ruptured brain arteriovenous malformations: A case report

Andi Kurnia Bintang, Ashari Bahar, Muhammad Akbar, Gita Vita Soraya, Anthony Gunawan, Nurussyariah Hammado, Mochammad Erwin Rachman, Zulvikar Syambani Ulhaq

Specialty type: Neurosciences

Provenance and peer review:

Unsolicited article; Externally peer reviewed.

Peer-review model: Single blind

Peer-review report's scientific quality classification

Grade A (Excellent): 0

Grade B (Very good): 0

Grade C (Good): C, C

Grade D (Fair): 0

Grade E (Poor): 0

P-Reviewer: Kumar S, India; Sidoti A

Received: October 7, 2022

Peer-review started: October 7, 2022

First decision: November 22, 2022

Revised: December 7, 2022

Accepted: February 22, 2023

Article in press: February 22, 2023

Published online: March 26, 2023



Andi Kurnia Bintang, Ashari Bahar, Muhammad Akbar, Gita Vita Soraya, Anthony Gunawan, Nurussyariah Hammado, Mochammad Erwin Rachman, Department of Neurology, Hasanuddin University, Makassar 90245, Indonesia

Gita Vita Soraya, Department of Biochemistry, Faculty of Medicine, Hasanuddin University, Makassar 90245, Indonesia

Nurussyariah Hammado, Faculty of Health and Sport Science, State University of Makassar, Makassar 90222, Indonesia

Mochammad Erwin Rachman, Faculty of Medicine, Muslim University of Indonesia, Makassar 90231, Indonesia

Zulvikar Syambani Ulhaq, Research Center for Preclinical and Clinical Medicine, National Research and Innovation Agency Republic of Indonesia, Cibinong 16911, Indonesia

Zulvikar Syambani Ulhaq, Laboratory of Developmental Disorders and Toxicology, Kyushu University, Fukuoka 8190395, Japan

Zulvikar Syambani Ulhaq, Department of Biomedical Science, Faculty of Medicine and Health Sciences, Maulana Malik Ibrahim State Islamic University, Malang 65144, Indonesia

Corresponding author: Ashari Bahar, MD, Consultant Physician-Scientist, Department of Neurology, Hasanuddin University, Jl. Perintis Kemerdekaan No.KM.10, Makassar 90245, Indonesia. asharibahar@med.unhas.ac.id

Abstract

BACKGROUND

Brain arteriovenous malformations (bAVMs) remains one of the most prevalent causes of intracranial hemorrhage and stroke-like syndromes in the young adult population. Although it has been agreed upon that definitive treatment using either single or multi-modal approach is warranted for successful bAVM management, much debate still revolves regarding the optimal timing of definitive treatment.

CASE SUMMARY


In this report, we present a case of delayed, definitive endovascular treatment for ruptured bAVM in a 21-year-old female, 3 mo post-ictus. The bAVM, with a left

pericallosal feeding artery and cortical draining veins, was successfully obliterated through embolization using the Onyx 18. On follow-up the patient has recommenced her daily activities and experiences only mild occasional headaches with mild motor deficits. The report leads to our review on an important issue regarding the optimal timing of ruptured bAVM definitive management and bring forward the current evidence available on delayed *vs* immediate definitive bAVM intervention. We also highlight current issues that need to be addressed for clearer guidelines on definitive therapy initiation.

CONCLUSION

Current treatment paradigms of ruptured bAVM remains elusive, with substantial heterogeneity in the current literature. A consensus on the definition of “acute” *vs* “delayed”, management goal, follow-up length and outcome parameters are required to support formation of a clear paradigm.

Key Words: Brain arteriovenous malformation; Ruptured brain arteriovenous malformation; Definitive intervention; Endovascular treatment; Case report

 **Open Access Author(s) 2023.** Published by Baishideng Publishing Group Inc. All rights reserved.

Core Tip: In this case report, we present an example of successful delayed management of a ruptured brain arteriovenous malformation (bAVM) in a young female. The case is followed by an updated review regarding current “delayed” and “immediate” definitive interventions for bAVMs and problems associated with the current data on the effectivity of these paradigms.

Citation: Bintang AK, Bahar A, Akbar M, Soraya GV, Gunawan A, Hammad N, Rachman ME, Ulhaq ZS. Delayed versus immediate intervention of ruptured brain arteriovenous malformations: A case report. *World J Clin Cases* 2023; 11(9): 1992-2001

URL: <https://www.wjgnet.com/2307-8960/full/v11/i9/1992.htm>

DOI: <https://dx.doi.org/10.12998/wjcc.v11.i9.1992>

INTRODUCTION

Brain arteriovenous malformations (bAVMs) continue to be one of the most prevalent causes of intracranial hemorrhage and stroke-like syndromes in the young adult population. It is defined as an anomalous network or nidus occurring within the brain parenchyma, in which a high-flow shunt or bypass occurs between the feeding artery to the veins. A large majority of bAVMs manifest as intracranial hemorrhage as the presenting symptom, due to rupture of the malformation. Hemorrhagic bAVMs have been shown to result in a morbidity rate of 30%-50% and mortality rate of 10%-30% [1]. Additionally, hemorrhagic bAVMs have a re-rupture risk of more than 4.8% per year [2,3].

Definitive treatment of bAVMs consist of three main modalities, namely endovascular embolization, stereotactic radiotherapy, and microsurgical resection or extirpation of the malformation, with the goal of complete nidus obliteration and minimized hemorrhage recurrence. Although it has been agreed upon that definitive treatment using either single or multi-modal approach is warranted for successful bAVM management, much debate still revolves regarding the optimal timing of definitive treatment.

Some indications warrant immediate definitive treatment, such as massive hemorrhage that implies a life-threatening mass effect, rapid neurological deterioration, or the presence of high-risk aneurysms, in which surgical evacuation can be performed in conjunction with definitive resection of small, superficial bAVMs. However, other cases may fall into the category of gray areas for immediate treatment. In fact, many interventionists and surgeons prefer delayed definitive treatment, when possible, due to easier visualization and high success rates. The current guideline on the management of bAVMs has acknowledged the lack of evidence to direct decisions in this setting [2], although some reports have suggested an ideal interval of 2-6 wk from rupture for removal of the bAVM [2,4,5], and that immediate removal may be associated with larger mortality and morbidity risk [5]. Unfortunately, more data is needed to prove either the benefits or disadvantages of both approaches.

Here we present a case report of a successful, delayed, exclusively endovascular management in a young, 21-year-old female with a ruptured bAVM of 3 mo onset. We then emphasize on this highly debatable topic with an updated literature review on the current evidence regarding outcomes of definitive treatment using either of the three modalities.

CASE PRESENTATION

Chief complaints

A 21-year-old female presented to Dr. Wahidin Sudirohusodo General Hospital, Makassar, Indonesia, in September 2021 with a chief complaint of weakness on the right side of her body, in addition to right-sided hypoesthesia and occasional headaches.

History of present illness

The complaints were first experienced 3 mo prior, with sudden onset, while the patient was performing her daily activities as a college student. She also recalled other symptoms upon onset, such as headache, transient vision loss, slurred speech, and vomiting. At the time, she experienced a brief period of loss of consciousness and was treated conservatively at her local health care center due to lack of imaging modalities.

History of past illness

The patient had no prior history of trauma, infection, hypertension, diabetes, or stroke.

Personal and family history

The patient had no significant personal or family history to disclose.

Physical examination

On presentation at our center, her vital signs were normal. The neurological bedside examination revealed a GCS score of 15, no meningeal signs, and good cognitive function. Her cranial nerve assessment was within normal limits. The motor strength assessment showed weakness on the right side with a strength score of 4 on the right upper and lower extremities. The right extremities also showed increased tone and physiologic reflexes. No pathologic reflexes were observed. The exam also showed right sided hypoesthesia. Autonomic function was within normal limits.

Laboratory examinations

Laboratory tests, chest X-rays, and electrocardiography exams showed no abnormal findings.

Imaging examinations

The first imaging examination was a non-contrast head computed tomography (CT) scan performed a few days after the onset, at the patient's regional hospital. The exam revealed an intracerebral hematoma of the left cerebral hemisphere (Figure 1). Due to the rise in COVID-19 cases at the time, her referral to Dr. Wahidin Sudirohusodo General Hospital for further investigation and definitive therapy was delayed based on her family's decision, and she was given conservative treatment.

A head CT angiography (Figure 2) was performed approximately 2 mo after onset, revealing the presence of an arteriovenous malformation (AVM) on the left frontal lobe with a feeding artery from the left anterior cerebral artery, draining into the superior sagittal sinus.

We performed a digital subtraction angiography (DSA) on the patient a few days after her admission in our center (Figure 3). The DSA confirmed that the bAVM fed off the left pericallosal artery, with two draining veins, one towards the cortical vein while the other has undergone stenosis. We graded the AVM as a Spetzler-Martin Grade II AVM.

FINAL DIAGNOSIS

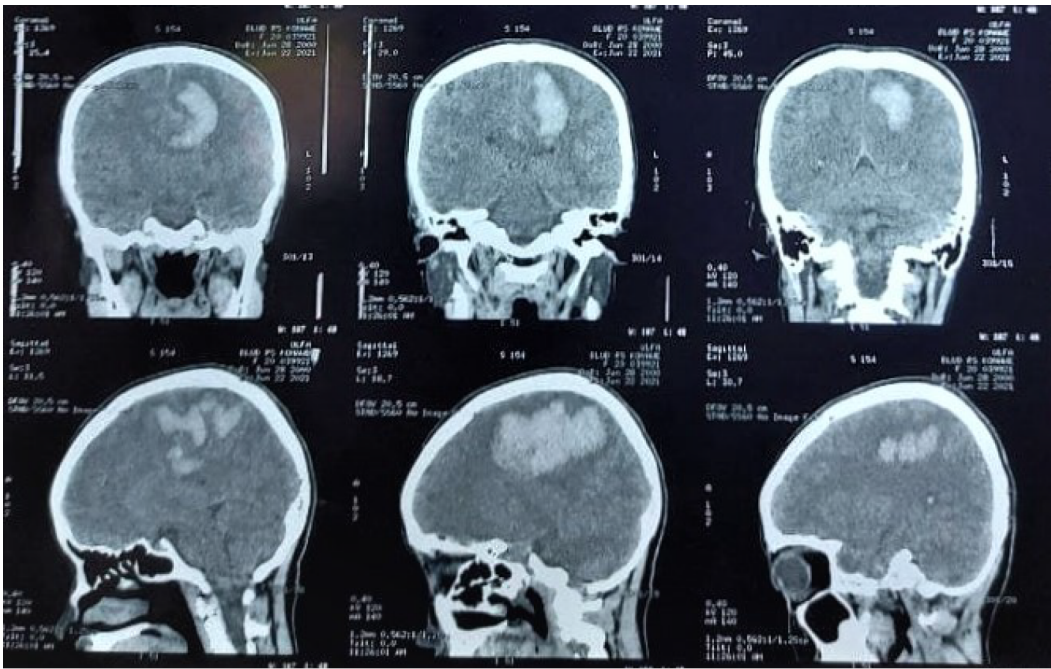
Based on the clinical findings, the patient was diagnosed with bAVM.

TREATMENT

The patient was subjected to a definitive therapy of embolization on the left pericallosal artery using the Onyx 18 until the nidus and draining vein can no longer be visualized (Figure 4). The patient was tolerant of the whole procedure, and no additional deficits were experienced throughout her care, and was discharged from the hospital a few days following embolization.

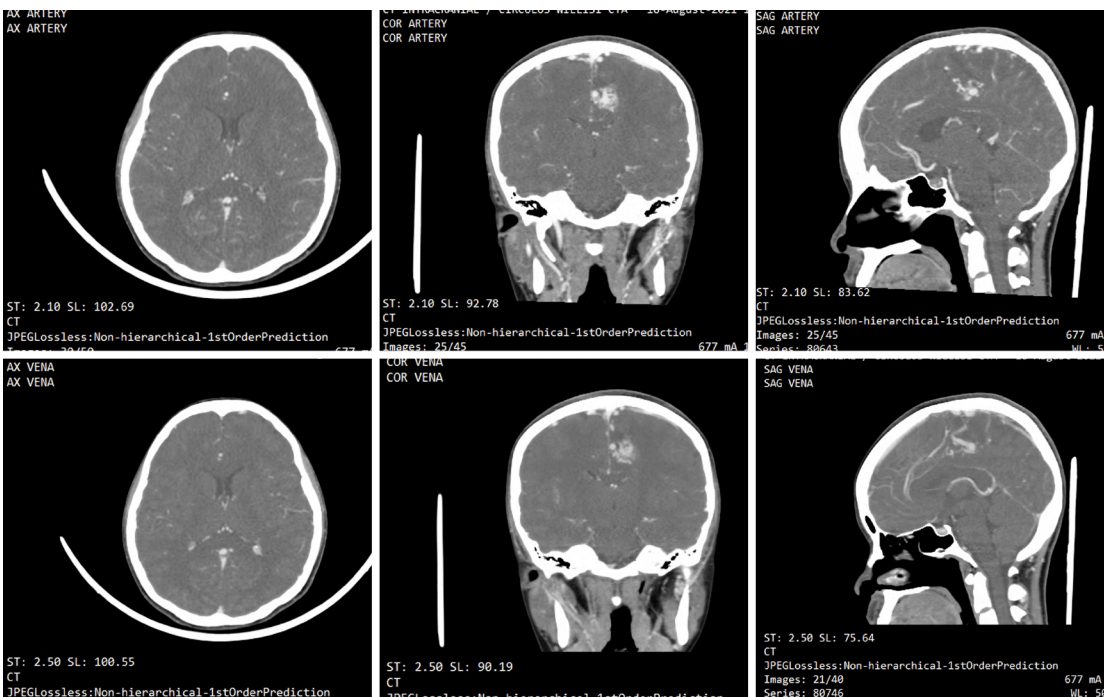
OUTCOME AND FOLLOW-UP

The patient returned 3 mo after the procedure for a follow-up visit to the Neurology Outpatient Clinic of Dr. Wahidin Sudirohusodo General Hospital. Her follow-up CT-scan revealed encephalomalacia of



DOI: 10.12998/wjcc.v11.i9.1992 Copyright ©The Author(s) 2023.

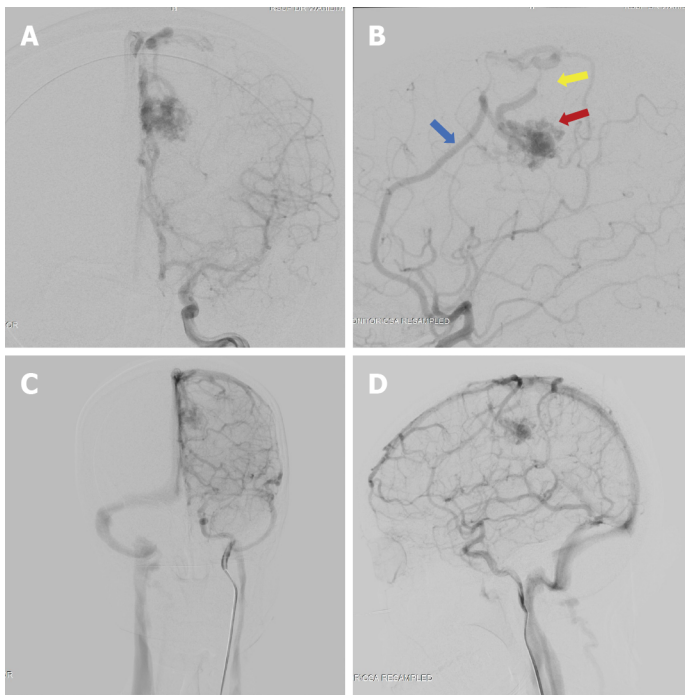
Figure 1 Head non-contrast computed tomography scan on onset (3 mo prior to presentation at our center), revealing extensive intracerebral hematoma of the left cerebral hemisphere.



DOI: 10.12998/wjcc.v11.i9.1992 Copyright ©The Author(s) 2023.

Figure 2 Subsequent head computed tomography angiography was performed 2 mo after onset, revealing the brain arteriovenous malformation, with a feeding artery from the left anterior cerebral artery, draining into the superior sagittal sinus.

the parasagittal region at the left frontal and parietal lobes with mild dilatation of the left lateral ventricle (Figure 5). And to date, approximately 1 year after the procedure, the patient has experienced no rebleeding. She currently lives with minor motor deficit resulting in abnormal gait, and experiences occasional headaches which are manageable with over-the-counter therapy (Glasgow Outcome Scale Score = 2).



DOI: 10.12998/wjcc.v11.i9.1992 Copyright ©The Author(s) 2023.

Figure 3 Digital subtraction angiography results of the patient. The digital subtraction angiography image revealed the presence of an arteriovenous malformation (red arrow) feeding off the left pericallosal artery (blue arrow) and draining towards the cortical vein and a stenotic vein (yellow arrow). A: Late arterial phase antero-posterior view; B: Late arterial phase, lateral view; C: Late venous phase, antero-posterior view; D: Late venous phase, lateral view.

DISCUSSION

The case we presented is one of the many ruptured bAVM cases encountered in our center that was successfully managed using delayed definitive treatment. The 21-year-old female experienced an intracerebral hematoma due to the bAVM rupture, leading to neurological deficits in the form of right-sided weakness and hypoesthesia. The bAVM was visualized on CT-angiography, then gold-standard DSA and definitive endovascular treatment was performed 3 mo after the rupture. The bAVM was treated successfully and the patient was able to recommence her daily activities.

In this instance, the delay to definitive investigations and therapy was coincidental, due to the high wave of the COVID-19 pandemic. But on many occasions, the delay is more deliberate, with interventionists arguing against immediate definitive intervention due to difficulties associated with vascular visualization during acute stages of hematoma. Despite the ongoing approach of either delayed or immediate treatment, there still is insufficient evidence to provide definite recommendations.

In this section, we present the current evidence regarding immediate and delayed treatment of bAVMs. Whilst there is currently a lack of studies comparing the two paradigm approaches, we have summarized individual studies looking at either of the two approaches when feasible, with results summarized in Table 1[6-15]. Traditionally, indications for emergency or immediate intervention of ruptured bAVMs include patients with life-threatening hematoma and its associated mass effects, deteriorating neurological status, and the presence of aneurysms[5,8]. In a state of emergency described above, there is no ambiguity, and the decision for immediate evacuation or decompressive craniectomy is clear. In conjunction with the emergency evacuation, extirpation of small superficial bAVMs is typically performed. The question that remains is whether immediate resection or obliteration of the bAVM is more beneficial in patients that do not have any life-threatening indications. Some experts have stated that acute definitive management is required for a good outcome, arguing that treatment delay require patients to recover twice, both from the hemorrhage and from the subsequent definitive intervention[16]. Some centers have argued that early surgery can achieve better rebleeding protection, reduce length-of-stay, and allow earlier initiation of rehabilitation.

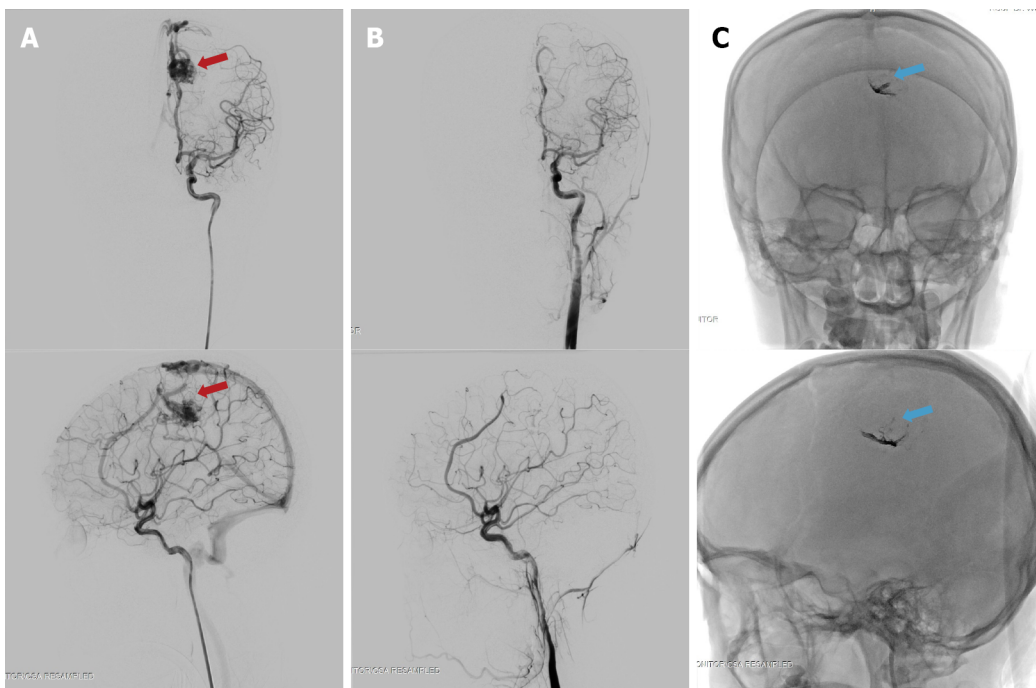
On the other hand, arguments supporting delayed definitive treatment state that surgical management of bAVMs should be performed following recovery of the brain from injury and to wait for stabilization of the patient's general condition. A highly variable rest period of 1-6 wk between hemorrhage and definitive treatment is generally advocated in several literatures[4,15,17]. There are several other issues associated with acute interventions such as secondary edema and challenging visualization of compressed vessels, and therefore, delaying the intervention allows edema reduction that is most pronounced in the early days post hemorrhage[5]. There are also concerning observations regarding the hazardous consequences of early intervention, that have led to preventable neurological

Table 1 Summary of the current evidence on delayed versus immediate treatment of ruptured brain arteriovenous malformations

Ref.	Time from ictus (rupture)	bAVM type and SMG	Modality of definitive treatments	Number of subjects	Age	Outcome	Follow-up period	Result
Bartolomeo <i>et al</i> [6], 2021	48 h; > 48 h	I-IV	Surgery; multimodal evacuation of hematoma	25	Mean age 38 and 45.55	mRS score	3 mo and 1 yr	Surgery after rest period is better, but early surgery seems reasonable for young patients
Mansur <i>et al</i> [7], 2021	48 h; > 48 h	I-IV	Targeted embolization; surgery; combination of delayed therapy; observation	32 acute; 284 non-acute	Mean age of acute: 32; non acute: 284	Change in mRS score and clinical outcome/re-rupture	Mean 3.2 ± 1.4 yr	Delayed curative treatment preferred. Acute targeted embolization warranted for weak points
Beecher <i>et al</i> [8], 2017	Delayed only: Minimal 4 wk post-hemorrhage	N/A	Radiation; surgery; embolization	102	N/A	Time to treatment failure (re-hemorrhage or neurological decline)	Median 248 d	6 (5.8%) new hemorrhage. Authors in support of delaying treatment for at least weeks to allow for neurologic improvement prior to intervention
Bir <i>et al</i> [9], 2016	< 24 h; 24-48 h; > 48 h	I-IV	Embolization; GK SRS; microsurgical resection	78	Median age 45	Mean mRS grading	Mean mo 45.17 (1-223)	Significant difference in mean mRS: Group < 24h vs > 48h (P = 0.01); Group 24-48 h vs > 48 h (P = 0.03)
Todnem <i>et al</i> [10], 2019	Immediate embolization (time not defined) followed by delayed GK-SRS	III-IV	Embolization and SRS combination	16	Mean age 46.63 yr	mRS score	45.4 21.43 mo	Improvement of mRS score and no recurrent hemorrhage
van Rooij <i>et al</i> [11], 2012	Acute phase: Within 10 d of ictus	N/A	Embolization with either coils or Onyx	23	Mean age 42 yr	Obliteration status; hemorrhage recurrence; mortality	21 mo mean	1 death (following surgical evacuation of frontal hematoma); 13 patients had complete obliteration; No new hemorrhage
Andreou <i>et al</i> [12], 2008	Median 2 wk after ictus (range 1-28 wk)	Micro-AVM; SMG N/A	Embolization	25	N/A	Procedure-related complications; obliteration status; re-hemorrhage	6 mo	3 complications; 22 complete obliterations; 2 recurrences
Stemer <i>et al</i> [13], 2013	Acute phase Median 4 d after ictus (Range 8-75)	I-VI	Embolization (Onyx only)	21	Mean age 38 yr	Procedure-related complications; obliteration status; re-hemorrhage; GOS	7.5 mo mean	2 asymptomatic complications; 0 new hemorrhage; 7 complete obliterations after the first procedure; mean GOS improvement from 4.0 on presentation to 4.4 after first procedure
Pavesi <i>et al</i> [14], 2009	Acute phase (within 6 d of ictus)	I-II	Radical AVM surgical removal + hematoma evacuation	27	Mean age 41.3 yr	GOS; rehemorrhage; mortality	22 mo mean	85% favorable functional outcome (GOS: good recovery - moderate disability); 2 re-hemorrhages; 7.4% mortality
Kuhmonen <i>et al</i> [15], 2005	Acute phase (within 4 d of ictus)	1-V	Craniotomy and extirpation; ventricular drainage; embolization	49	Mean age 32.8	GOS; mortality	2-3 mo	More than half of the patients had a good functional outcome; Mortality 12.2 %

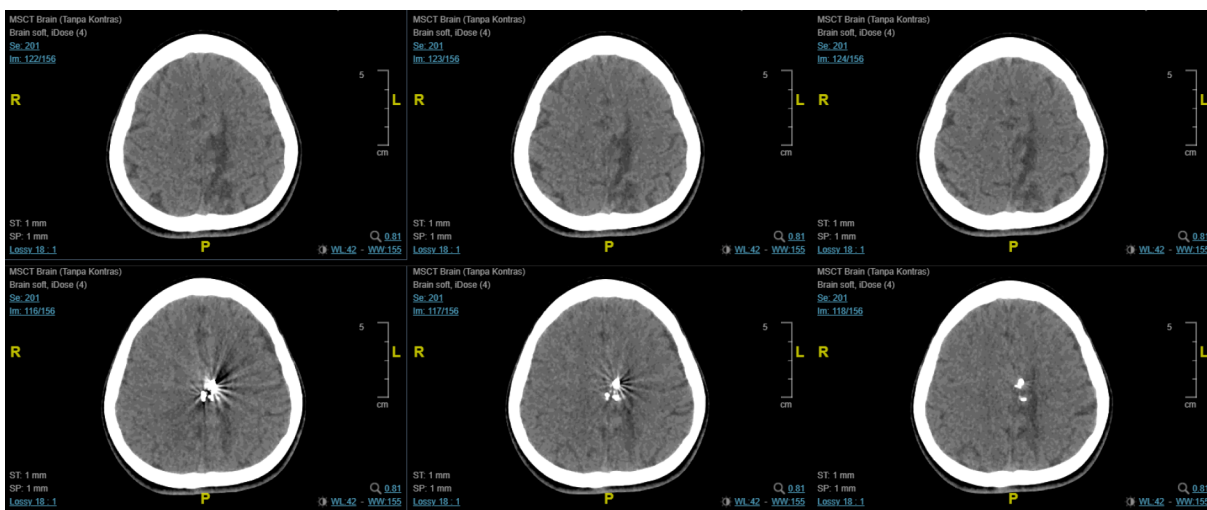
bAVM: Brain arteriovenous malformation; GOS: Glasgow outcome scale; GK-SRS: Gamma-knife stereotactic radiation surgery; SMG: Spletzer-Martin Grade.

deficits[5]. And finally, several unique conditions may place the patient as a candidate for delayed definitive treatment, such as bAVMs in pregnancy that typically require delay of intervention until post-gestation[18].



DOI: 10.12998/wjcc.v11.i9.1992 Copyright ©The Author(s) 2023.

Figure 4 Digital subtraction angiography images before and after the embolization procedure on the brain arteriovenous malformation at approximately 3 mo post-ictus. The embolization procedure was performed on the left pericallosal artery using the Onyx 18 until the nidus and draining vein can no longer be visualized. A: The nidus, before embolization (red arrow) on antero-posterior (top) and lateral (bottom) view of arterial phase; B: Complete obliteration of the nidus after embolization on the arterial phase, antero-posterior (top) and lateral (bottom) view; C: The onyx cast visible through fluoroscopy, on antero-posterior (top) and lateral (bottom) view, indicated with blue arrow.



DOI: 10.12998/wjcc.v11.i9.1992 Copyright ©The Author(s) 2023.

Figure 5 Follow-up computed tomography-scan revealed encephalomalacia of the parasagittal region at the left frontal and parietal lobes with mild dilatation of the left lateral ventricle. A hyperdense blooming artefact is visualized due to the Onyx cast.

Despite the ongoing debate of early *vs* delayed definitive bAVM management, there remains a lack of studies comparing the two approaches and its outcome, especially those performed in a single cohort. The spontaneous supratentorial lobar intracerebral hematomas trial has demonstrated that relative to early surgery, delayed hematoma surgery leads to deterioration. However, its sample population did not include those with hematoma due to AVM associated bleeding[19].

In order to pave the way for more definitive recommendations on the management of AVM ruptures, we propose that several urgent matters need to be addressed. Firstly, a clear consensus on the definition of immediate and delayed definitive treatment in bAVM management is urgently needed. In other words, when is a procedure considered immediate and when is it considered delayed? Most of the included studies in this report had varying time frames of patient inclusion. Additionally, a systematic

approach to this topic is still hindered by the complexity of the management of bAVMs. Until today, intervention of ruptured bAVM is highly multidisciplinary, varies on a case-by-case basis, and is highly dependent on the clinical status, the size and location of the bAVM and the feeding-drainage pattern. This leads to the large heterogeneity in the literature of bAVM investigations. Current clinical trials on bAVM is highly limited, with the largest known trial only focusing on unruptured bAVM (A Randomized Trial of Unruptured Brain AVMs or the ARUBA trial)[20]. Even so, the trial continues to be criticized due to methodological deficiencies[21], only further emphasizing the complexity of bAVM management and investigations into the management.

Outcomes of treatment success also needs to be more strictly defined. Commonly measured outcomes include nidus obliteration (which requires additional radiographic evidence in the follow-up period), hemorrhage recurrence, functional status or neurological sequelae, and mortality. A consensus on defined parameters, in addition to a pre-defined length of follow-up will greatly assist in the acquirement of homogenous data that is urgently needed to answer the current questions in regard to which time approach is more superior, with an end goal of a clear treatment paradigm for ruptured bAVM.

Recurrent hemorrhage itself is an important issue in bAVM management, and was shown to occur at an annual rate of 33% for males and 10% for females[22]. Beecher *et al*[8] identified obesity as the main predictor of AVM re-bleeding ($P = 0.048$). Meanwhile studies focusing on early intervention has identified age as a factor that significantly affects outcome[15]. While it remains unclear whether late or immediate approaches differ in re-hemorrhage rates, early intervention studies have claimed that the approach minimizes complications from delayed venous occlusion and is more efficient as it does not require multiple anesthetics or hospital admissions.

The decision to delay treatment may be supported by the difficulties associated with performing gold-standard angiography in the hyperacute phase. To illustrate, in a cohort described by Andreou *et al* [12], of all 25 patients with acute presentation of micro-bAVM rupture, only 17 was diagnostic of the AVM. In the acute phase, cerebral lumens undergo compression or destruction due to the surrounding hematoma. Additionally, patients may also experience vascular thrombosis or spasm, further complicating clear visualization of the lesion. Some other reasons include delayed cross-institutional referral, need for additional diagnostic imaging, patient preference, or pregnancy[8].

A recent retrospective study has shown that delayed conclusive treatment yields more favorable functional outcome[6], and that both approaches are influenced by different factors, wherein early intervention is influenced by the ICH score, while the delayed intervention is influenced by the bAVM microarchitecture as defined by the Spetzler-Martin grades. In said study, the mortality rate between the early and delayed group was also significantly different, although this should be interpreted with caution, due to the higher likelihood of high-risk emergency comorbidities accompanying cases of early treatment. Another recent study comparing delayed *vs* acute approaches showed that delayed treatment had significantly higher nidus obliteration rates and were less likely to require multiple treatments[7]. No significant difference was observed in the re-rupture rate or mortality. Interestingly, the study stated that in patients with the acute targeted approach, it's not the acute timing itself rather than the targeted approach that provided a protective effect on the acutely managed patients.

Although this review has focused mainly on the timing of treatment, there has been some interesting development of molecular investigations into bAVM pathomechanism using high-throughput next-generation sequencing and pathway analysis, which may have future implications in the future personalized management of bAVM[23,24]. An example is the recent discovery on the importance of TGF- β signaling in bAVM pathogenesis[24,25]. In the future, as more exploration into bAVM mechanism will be needed to improve personalized management of bAVM.

To our knowledge, this is the first review to summarize the current literature on the topic of delayed *vs* immediate definitive intervention for ruptured bAVMs. Clearly, unless a consensus is reached on the questions raised above, heterogeneity will continue to exist, and a clear paradigm on the timing of definitive treatment of bAVM will continue to be delayed.

CONCLUSION

In this case report and review, we illustrate a common scenario of a delayed approach to bAVM definitive treatment using an endovascular approach. The current treatment paradigm of ruptured bAVM remains elusive, with many interventionists favoring either a delayed or acute treatment approach. There is substantial heterogeneity in the current literature, rendering it highly difficult to determine which of the following time-based approach is more superior. We believe that a consensus on the definition of acute *vs* delayed, the goal of management in ruptured bAVM, the follow-up length and outcome parameters need to be determined in order to acquire homogenous data that can support the formation of a clear treatment paradigm.

ACKNOWLEDGEMENTS

We would like to thank the patient who has participated in this study.

FOOTNOTES

Author contributions: Bahar A and Bintang AK conceptualized and supervised the study, performed the data collection and finalized the manuscript; Bahar A, Soraya GV and Bintang AK drafted the manuscript and revised the manuscript; Ulhaq ZS and Soraya GV performed the systematic review; Gunawan A, Akbar M, Hammado N, Rachman ME, and Ulhaq ZS revised the manuscript and provided substantial input; all authors have read and approved the final manuscript.

Informed consent statement: The subject described in the case report has provided written consent for publication.

Conflict-of-interest statement: The authors declare no conflict of interest.

CARE Checklist (2016) statement: The authors have read the CARE Checklist (2016), and the manuscript was prepared and revised according to the CARE Checklist (2016).

Open-Access: This article is an open-access article that was selected by an in-house editor and fully peer-reviewed by external reviewers. It is distributed in accordance with the Creative Commons Attribution NonCommercial (CC BY-NC 4.0) license, which permits others to distribute, remix, adapt, build upon this work non-commercially, and license their derivative works on different terms, provided the original work is properly cited and the use is non-commercial. See: <https://creativecommons.org/licenses/by-nc/4.0/>

Country/Territory of origin: Indonesia

ORCID number: Ashari Bahar 0000-0001-8994-1816; Gita Vita Soraya 0000-0002-2656-4176; Zulvikar Syambani Ulhaq 0000-0002-2659-1940.

S-Editor: Chang KL

L-Editor: A

P-Editor: Chang KL

REFERENCES

- 1 **Stapf C**, Mast H, Sciacca RR, Choi JH, Khaw AV, Connolly ES, Pile-Spellman J, Mohr JP. Predictors of hemorrhage in patients with untreated brain arteriovenous malformation. *Neurology* 2006; **66**: 1350-1355 [PMID: 16682666 DOI: 10.1212/01.wnl.0000210524.68507.87]
- 2 **Derdeyn CP**, Zipfel GJ, Albuquerque FC, Cooke DL, Feldmann E, Sheehan JP, Torner JC; American Heart Association Stroke Council. Management of Brain Arteriovenous Malformations: A Scientific Statement for Healthcare Professionals From the American Heart Association/American Stroke Association. *Stroke* 2017; **48**: e200-e224 [PMID: 28642352 DOI: 10.1161/STR.0000000000000134]
- 3 **Kim H**, Al-Shahi Salman R, McCulloch CE, Stapf C, Young WL; MARS Coinvestigators. Untreated brain arteriovenous malformation: patient-level meta-analysis of hemorrhage predictors. *Neurology* 2014; **83**: 590-597 [PMID: 25015366 DOI: 10.1212/WNL.0000000000000688]
- 4 **Zacharia BE**, Vaughan KA, Jacoby A, Hickman ZL, Bodmer D, Connolly ES Jr. Management of ruptured brain arteriovenous malformations. *Curr Atheroscler Rep* 2012; **14**: 335-342 [PMID: 22623087 DOI: 10.1007/s11883-012-0257-9]
- 5 **Aoun SG**, Bendok BR, Batjer HH. Acute management of ruptured arteriovenous malformations and dural arteriovenous fistulas. *Neurosurg Clin N Am* 2012; **23**: 87-103 [PMID: 22107861 DOI: 10.1016/j.nec.2011.09.013]
- 6 **Di Bartolomeo A**, Scafa AK, Giugliano M, Dugoni DE, Ruggieri AG, Delfini R. Ruptured Brain Arteriovenous Malformations: Surgical Timing and Outcomes-A Retrospective Study of 25 Cases. *J Neurosci Rural Pract* 2021; **12**: 4-11 [PMID: 33551615 DOI: 10.1055/s-0040-1716792]
- 7 **Mansur A**, Kostynskyy A, Krings T, Agid R, Radovanovic I, Mendes Pereira V. The safety profile and angioarchitectural changes after acute targeted embolization of ruptured arteriovenous malformations. *J Neurosurg* 2021; 1-10 [PMID: 33962377 DOI: 10.3171/2020.9.JNS201558]
- 8 **Beecher JS**, Lyon K, Ban VS, Vance A, McDougall CM, Whitworth LA, White JA, Samson D, Batjer HH, Welch BG. Delayed treatment of ruptured brain AVMs: is it ok to wait? *J Neurosurg* 2018; **128**: 999-1005 [PMID: 28686111 DOI: 10.3171/2017.1.JNS16745]
- 9 **Bir SC**, Maiti TK, Konar S, Nanda A. Overall outcomes following early interventions for intracranial arteriovenous malformations with hematomas. *J Clin Neurosci* 2016; **23**: 95-100 [PMID: 26321303 DOI: 10.1016/j.jocn.2015.05.041]
- 10 **Todnem N**, Ward A, Nahhas M, Vender JR, Alleyne CH, Rahimi SY. A Retrospective Cohort Analysis of Hemorrhagic Arteriovenous Malformations Treated with Combined Endovascular Embolization and Gamma Knife Stereotactic Radiosurgery. *World Neurosurg* 2019; **122**: e713-e722 [PMID: 30394359 DOI: 10.1016/j.wneu.2018.10.125]

- 11 **van Rooij WJ**, Jacobs S, Sluzewski M, Beute GN, van der Pol B. Endovascular treatment of ruptured brain AVMs in the acute phase of hemorrhage. *AJNR Am J Neuroradiol* 2012; **33**: 1162-1166 [PMID: 22282446 DOI: 10.3174/ajnr.A2995]
- 12 **Andreou A**, Ioannidis I, Lalloo S, Nickolaos N, Byrne JV. Endovascular treatment of intracranial microarteriovenous malformations. *J Neurosurg* 2008; **109**: 1091-1097 [PMID: 19035724 DOI: 10.3171/JNS.2008.109.12.1091]
- 13 **Stemer AB**, Bank WO, Armonda RA, Liu AH, Herzig DW, Bell RS. Acute embolization of ruptured brain arteriovenous malformations. *J Neurointerv Surg* 2013; **5**: 196-200 [PMID: 22406978 DOI: 10.1136/neurintsurg-2011-010214]
- 14 **Pavesi G**, Rustemi O, Berlucchi S, Frigo AC, Gerunda V, Scienza R. Acute surgical removal of low-grade (Spetzler-Martin I-II) bleeding arteriovenous malformations. *Surg Neurol* 2009; **72**: 662-667 [PMID: 19604554 DOI: 10.1016/j.surneu.2009.03.035]
- 15 **Kuhmonen J**, Piippo A, Väärt K, Karatas A, Ishii K, Winkler P, Niemelä M, Porras M, Hernesniemi J. Early surgery for ruptured cerebral arteriovenous malformations. *Acta Neurochir Suppl* 2005; **94**: 111-114 [PMID: 16060249 DOI: 10.1007/s211-27911-3_17]
- 16 **Hafez A**, Oulasvirta E, Koroknay-Pál P, Niemelä M, Hernesniemi J, Laakso A. Timing of surgery for ruptured supratentorial arteriovenous malformations. *Acta Neurochir (Wien)* 2017; **159**: 2103-2112 [PMID: 28894970 DOI: 10.1007/s00701-017-3315-9]
- 17 **Ogilvy CS**, Stieg PE, Awad I, Brown RD Jr, Kondziolka D, Rosenwasser R, Young WL, Hademenos G; Stroke Council, American Stroke Association. Recommendations for the management of intracranial arteriovenous malformations: a statement for healthcare professionals from a special writing group of the Stroke Council, American Stroke Association. *Circulation* 2001; **103**: 2644-2657 [PMID: 11382737 DOI: 10.1161/01.cir.103.21.2644]
- 18 **Salvati A**, Ferrari C, Chiumarulo L, Medicamento N, Dicuonzo F, De Blasi R. Endovascular treatment of brain arteriovenous malformations ruptured during pregnancy--a report of two cases. *J Neurol Sci* 2011; **308**: 158-161 [PMID: 21719029 DOI: 10.1016/j.jns.2011.06.015]
- 19 **Mendelow AD**, Gregson BA, Fernandes HM, Murray GD, Teasdale GM, Hope DT, Karimi A, Shaw MD, Barer DH; STICH investigators. Early surgery versus initial conservative treatment in patients with spontaneous supratentorial intracerebral haematomas in the International Surgical Trial in Intracerebral Haemorrhage (STICH): a randomised trial. *Lancet* 2005; **365**: 387-397 [PMID: 15680453 DOI: 10.1016/S0140-6736(05)17826-X]
- 20 **Mohr JP**, Parides MK, Stapf C, Moquete E, Moy CS, Overbey JR, Al-Shahi Salman R, Vicaut E, Young WL, Houdart E, Cordonnier C, Stefani MA, Hartmann A, von Kummer R, Biondi A, Berkefeld J, Klijn CJ, Harkness K, Libman R, Barreau X, Moskowitz AJ; international ARUBA investigators. Medical management with or without interventional therapy for unruptured brain arteriovenous malformations (ARUBA): a multicentre, non-blinded, randomised trial. *Lancet* 2014; **383**: 614-621 [PMID: 24268105 DOI: 10.1016/S0140-6736(13)62302-8]
- 21 **Meling TR**, Proust F, Gruber A, Niemela M, Regli L, Roche PH, Vajkoczy P. On apples, oranges, and ARUBA. *Acta Neurochir (Wien)* 2014; **156**: 1775-1779 [PMID: 24890935 DOI: 10.1007/s00701-014-2140-7]
- 22 **Mast H**, Young WL, Koennecke HC, Sciacca RR, Osipov A, Pile-Spellman J, Hacein-Bey L, Duong H, Stein BM, Mohr JP. Risk of spontaneous haemorrhage after diagnosis of cerebral arteriovenous malformation. *Lancet* 1997; **350**: 1065-1068 [PMID: 10213548 DOI: 10.1016/S0140-6736(97)05390-7]
- 23 **Scimone C**, Donato L, Marino S, Alafaci C, D'Angelo R, Sidoti A. Vis-à-vis: a focus on genetic features of cerebral cavernous malformations and brain arteriovenous malformations pathogenesis. *Neurol Sci* 2019; **40**: 243-251 [PMID: 30523548 DOI: 10.1007/s10072-018-3674-x]
- 24 **Scimone C**, Donato L, Alafaci C, Granata F, Rinaldi C, Longo M, D'Angelo R, Sidoti A. High-Throughput Sequencing to Detect Novel Likely Gene-Disrupting Variants in Pathogenesis of Sporadic Brain Arteriovenous Malformations. *Front Genet* 2020; **11**: 146 [PMID: 32184807 DOI: 10.3389/fgene.2020.00146]
- 25 **Scimone C**, Granata F, Longo M, Mormina E, Turiaco C, Caragliano AA, Donato L, Sidoti A, D'Angelo R. Germline Mutation Enrichment in Pathways Controlling Endothelial Cell Homeostasis in Patients with Brain Arteriovenous Malformation: Implication for Molecular Diagnosis. *Int J Mol Sci* 2020; **21** [PMID: 32560555 DOI: 10.3390/ijms21124321]



Published by **Baishideng Publishing Group Inc**
7041 Koll Center Parkway, Suite 160, Pleasanton, CA 94566, USA

Telephone: +1-925-3991568

E-mail: bpgoffice@wjgnet.com

Help Desk: <https://www.f6publishing.com/helpdesk>

<https://www.wjgnet.com>



● **10% Overall Similarity**

Top sources found in the following databases:

- 7% Internet database
- Crossref database
- Crossref Posted Content database

TOP SOURCES

The sources with the highest number of matches within the submission. Overlapping sources will not be displayed.

1	shura.shu.ac.uk Internet	2%
2	Mai-Qing Yang, Zhi-Qiang Wang, Li-Qian Chen, Su-Mei Gao, Xing-Ning ... Crossref	2%
3	mafiadoc.com Internet	<1%
4	Xin Hong, You-Qi Ji, Meng-Yuan Chen, Xiao-Yu Gou, Yu-Mei Ge. " infec... Crossref	<1%
5	Yi Zeng, Lu-Chuan Chen, Zai-Sheng Ye, Jing-Yu Deng. "Examined lym... Crossref	<1%
6	Philip S. Barie. "Great News—At Last!", Surgical Infections, 10/2010 Crossref	<1%
7	K. Ebina. "Gangliocytoma of the pineal body a case report and review o... Crossref	<1%
8	researchonline.jcu.edu.au Internet	<1%
9	kjg.or.kr Internet	<1%

10	assets.researchsquare.com	Internet	<1%
11	anesth-pain-med.org	Internet	<1%
12	Wassan Nori, Ban H-Hameed. "Vaginal microbes confounders and impl...	Crossref	<1%
13	doaj.org	Internet	<1%
14	frontiersin.org	Internet	<1%
15	bmjopen.bmj.com	Internet	<1%
16	esc365.escardio.org	Internet	<1%
17	thejns.org	Internet	<1%
18	"New Trends of Surgery for Stroke and its Perioperative Management", ...	Crossref	<1%
19	Dasenbrock, Hormuzdiyar H., and Rose Du. "Presentation of Cerebral A...	Crossref	<1%
20	Iulian Prutianu, Teodora Alexa-Stratulat, Elena Octaviana Cristea, Andr...	Crossref	<1%
21	Mai Hashem, Mohamed El-Kassas. "Diagnosis, treatment protocols, an...	Crossref	<1%

● Excluded from Similarity Report

- Publications database
- Bibliographic material
- Cited material
- Manually excluded sources
- Submitted Works database
- Quoted material
- Small Matches (Less than 10 words)

EXCLUDED SOURCES

wjgnet.com	75%
Internet	
Andi Kurnia Bintang, Ashari Bahar, Muhammad Akbar, Gita Vita Soraya et al. "...	63%
Crossref	
ncbi.nlm.nih.gov	53%
Internet	
referencecitationanalysis.com	18%
Internet	
f6publishing.blob.core.windows.net	18%
Internet	
f6publishing.com	16%
Internet	
researchgate.net	15%
Internet	
bsdwebstorage.blob.core.windows.net	12%
Internet	
repository.wima.ac.id	12%
Internet	

digitalcommons.wustl.edu	12%
Internet	
eprints.whiterose.ac.uk	11%
Internet	
kumel.medlib.dsmc.or.kr	10%
Internet	
hdl.handle.net	10%
Internet	
repub.eur.nl	9%
Internet	
researchmap.jp	8%
Internet	
jdc.jefferson.edu	8%
Internet	
isabelclarke.org	8%
Internet	
boris.unibe.ch	8%
Internet	
readkong.com	8%
Internet	
ousar.lib.okayama-u.ac.jp	7%
Internet	
ro.ecu.edu.au	7%
Internet	

rodin.uca.es	7%
Internet	
westminsterresearch.westminster.ac.uk	7%
Internet	
pure.eur.nl	7%
Internet	
repozitorij.mef.unizg.hr	6%
Internet	
kclpure.kcl.ac.uk	6%
Internet	
air.unimi.it	6%
Internet	
doi.org	6%
Internet	
nur.nu.edu.kz	6%
Internet	
helda.helsinki.fi	6%
Internet	
Vaishali Aggarwal, Catalina Ardila Montoya, Vera S. Donnenberg, Shilpa Sant. ...	6%
Crossref	
dx.doi.org	5%
Internet	
tinyurl.com	5%
Internet	

opus.bibliothek.uni-augsburg.de	5%
Internet	
Min-Hee Choi, In-Young Yoon, Won-Joong Kim. "Ultrasound-guided intra-artic...	5%
Crossref	
Chien-Cheng Lai, Hsu-Wei Fang, Chih-Hung Chang, Jwo-Luen Pao, Chun-Chie...	5%
Crossref	
Ha-Jong Nam, Syeo-Young Wee. "Successful treatment of a rare subcutaneou...	5%
Crossref	
Jian-Hua Dai, Feng Qian, Lei Chen, Sen-Lin Xu, Xiao-Feng Feng, Hong-Bo Wu, ...	4%
Crossref	
Huan Wang, Yu-Zhong Hu, Xian-Wei Che, Liang Yu. "Motor cortex transcranial ...	4%
Crossref	
Zi-Yan Dong, Wei Shao, Yue Yuan, Li Lin, Xia Yu, Lang Cui, Zhen Zhen, Lu Gao. ...	4%
Crossref	
Yu Yao, Jun-Jie Ji, Hai-Yun Wang, Li-Jiang Sun, Gui-Ming Zhang. "Granulomat...	4%
Crossref	
Qiao-Yu Zhang, Lin-Ying Xu, Ming-Li Wang, Hua Cao, Xiao-Fei Ji. "Spontaneou...	4%
Crossref	
Shuai Dong, Yang-Chun Xu, Yuan-Chen Zhang, Jian-Xin Xia, Yan Mou. "Pembr...	4%
Crossref	
Xiao-Xi Li, Yun-Feng Yao, Hong-Yu Tan. "Anesthetic management of a patient ...	4%
Crossref	
Mariangela Rondanelli, Zaira Patelli, Clara Gasparri, Francesca Mansueto et al...	4%
Crossref	

pdfs.semanticscholar.org	4%
Internet	
Ren Shen, Jian-Hua Feng, Shan-Pu Yang. "Acromicric dysplasia caused by a ...	4%
Crossref	
Zhen-Ya Zhao, Yue-Xing Lai, Ping Xu. "Gastric ectopic pancreas combined wit...	4%
Crossref	
Jun Zheng, Qi-Yue Wu, Xia Zeng, Du-Fei Zhang. "Transient ischemic attack ind...	4%
Crossref	
Mai Li, Ping Su, Li-Ming Zhou. " Live births from fertilization-embryo transfer ...	4%
Crossref	
Shruthi Karthikeyan, Jeanne Shen, Kian Keyashian, John Gubatan. "Small bow...	4%
Crossref	
Dan Qiao, Xiao-Yan Liu, Lie Zheng, Ya-Li Zhang, Ren-Ye Que, Bing-Jing Ge, Ho...	4%
Crossref	
rcastoragev2.blob.core.windows.net	4%
Internet	
Pan Huang, Min Xu. "Four kinds of antibody positive paraneoplastic limbic en...	4%
Crossref	
Shuang-Zhu Lin, Mei-Jia Qian, Yan-Wei Wang, Qian-Dui Chen et al. " Children ...	4%
Crossref	
Qiang Shu, Jia-Nong Luo, Xiao-Ling Liu, Min Jing, Ting-Gang Mou, Fei Xie. "Ext...	4%
Crossref	
Ling-Li Li, Rui Xie, Fu-Qing Li, Cheng Huang, Bi-Guang Tuo, Hui-Chao Wu. "Easi...	4%
Crossref	

Cai-Hong Chen, Jing-Nan Chen, Hang-Gen Du, Dong-Liang Guo. "Isolated cere...	4%
Crossref	
Yi-Jie Wang, Chien-Peng Huang, Zhi-Jie Hong, Guo-Shiou Liao, Jyh-Cherng Yu...	4%
Crossref	
Jun-Yu Zhu, Jun Yan, Jian Xiao, Hai-Guang Jia, Hao-Jun Liang, Geng-Yan Xing...	4%
Crossref	
Jong-Hwan Hong, Sung-Chan Jung, Han-Seung Ryu, Tae-Sun Kim, Sung-Pil Jo...	4%
Crossref	
Chao Zhou, Shan Song, Jian-Feng Fu, Xue-Lian Zhao, Hua-Qin Liu, Huan-Shua...	4%
Crossref	
Yi-Wen Zhou, Yan-Yi Wang, Zhi-Feng He, Ming-Xing Lu, Gui-Feng Li, Huang Li. ...	4%
Crossref	
Shao-Yong Liu, Liu-Ling Hu, Shi-Jun Wang, Zhong-Li Liao. "Administration of ...	4%
Crossref	
Nicolas Yap San Min, Urba Rafi, Juan Wang, Bin He, Lei Fan. "Ochronotic arthr...	4%
Crossref	
lib.kobe-u.ac.jp	4%
Internet	
Metodija Sekulovski, Simona Bogdanova-Petrova, Monika Peshevaska-Sekulov...	4%
Crossref	
Le-Le Feng, Jie Du, Chen Wang, Shui-Li Wang. "Primary membranous nephroti...	4%
Crossref	
Xiao-Rong Tan, Juan Li, Hua-Wei Chen, Wei Luo, Nan Jiang, Zheng-Bo Wang, ...	4%
Crossref	

Yan Zeng, Jian Yang, Jun-Wen Zhang. "Endoscopic transluminal drainage and... Crossref	4%
Hazem Beji, Mohamed Fadhel Chtourou, Slim Zribi, Yassine Kallel, Mahdi Bou... Crossref	4%
Hai-Jun Zhang, Jin-Yi Li, Chao Wang, Guo-Qiang Zhong. "Microvesicles with ... Crossref	4%
Bo-Ya Chiu, Shu-Hung Chuang, Shih-Chang Chuang, Kung-Kai Kuo. "Laparosc... Crossref	4%
William Wang, Maria Korah, Kovi E Bessoff, Jeanne Shen, Joseph D Forrester. ... Crossref	3%
Jin-Lei Wang, Jia-Ping Yan, Xiang Li, Md Shahidul Islam, Jian-Bo Xiao, Lu Cai, ... Crossref	3%
Harumasa Nakazawa, Kohji Uzawa, Joho Tokumine, Alan Kawarai Lefor, Akira... Crossref	3%
A-Mao Tang, Jia-Ying Xu, Rong Wang, Yi-Min Li. "Treatment of a large area pe... Crossref	3%
I Nengah Wiadnyana Steven Christian, Michael, Kelvin Setiawan. "Cemento-o... Crossref	3%
Yu-Hong Xie, Ye-Min Zhang, Fan-Fan Fan, Xi-Yan Song, Lei Liu. "Functional rol... Crossref	3%
Xu-Ling Liu, Cheng-Feng Miao, Min Li, Peng Li. "Malignant transformation of p... Crossref	3%
Hamad Albagieh, Ashwag Aloyouny, Rana Alshagroud, Abdulaziz Alwakeel et ... Crossref	3%

Mohamed Aboel-Kassem F Abdelmegid, Mohamed M Bakr, Hamdy Shams-Ed...	3%
Crossref	
Shuang-Zhu Lin, Hong-Yan Xie, Yan-Lai Qu, Wen Gao, Wan-Qi Wang, Jia-Yi Li, ...	3%
Crossref	
healthdocbox.com	3%
Internet	
Jennifer Marie O'Donnell, Ernest Ekunseitan, Ishaan Swarup. "Factors associa...	3%
Crossref	
Li-Wei Dong, Yi-Yao Chen, Chao-Chao Chen, Zhi-Chao Ma et al. " Adenosine 2...	3%
Crossref	
Christopher Thomas Zoppo, Trenton Taros, Aaron Harman. "Top 50 most cite...	3%
Crossref	
Riccardo Vasapolli, Florent Ailloud, Sebastian Suerbaum, Jens Neumann et al....	3%
Crossref	
Giovanni Miotti, Marco Zeppieri, Giacomo Pederzani, Carlo Salati, Pier Camillo...	3%
Crossref	
Flora Maria Lorenzo Fortes, Raquel Rocha, Genoile Oliveira Santana. "Thiopuri...	3%
Crossref	
Dimitra Bacharaki, Ioannis Petrakis, Kostas Stylianou. "Redefying the therape...	3%
Crossref	
Wattana Leowattana, Tawithep Leowattana, PathompThep Leowattana. "Syst...	3%
Crossref	
referencecitationanalysis.com	3%
Internet	

moam.info	3%
Internet	
pubmed.ncbi.nlm.nih.gov	3%
Internet	
pesquisa.bvsalud.org	<1%
Internet	
mdpi.com	<1%
Internet	
npmj.org	<1%
Internet	
Ahmad Aoude, Hossein Ghanaati, Morteza Faghih Jouibari, Madjid Shakiba, M...	<1%
Crossref	
neurointervention.org	<1%
Internet	
mdpi-res.com	<1%
Internet	
Neurovascular Imaging, 2016.	<1%
Crossref	